

AFAST®: Introduction and Its Target Organ Approach & Fluid Scoring System

Gregory R. Lisciandro, DVM, Dipl. ABVP, Dipl. ACVECC

Hill Country Veterinary Specialists & CEO FASTVet.com, Spicewood, Texas USA

President, International Veterinary Point-of-care Ultrasound Society (IVPOCUS)

IVPOCUS.org (501c3 Non-profit)

Website FASTVet.com

Email LearnGlobalFAST@gmail.com

Cell 210.260.5576

Introduction

The clinical utility of AFAST®, its target-organ approach and its applied fluid scoring system in virtually all subsets of patients including trauma, triage (non-trauma) and tracking (monitoring) cases in the emergent and critical care settings will be reviewed. The previously published T³ designation encompasses these 3 subsets, Trauma, Triage (non-trauma), and Tracking (monitoring) and avoids the onslaught of confusing acronyms in human and now veterinary medicine in which similar abbreviated formats are given different acronyms when applied to different subsets of patients. However, AFAST® is in reality "an extension of the physical examination" and the T³ designation is unnecessary as more and more veterinarians understand its applications. Thus, AFAST® becomes a universal term that has *exact* clarity of its 5-acoustic windows or views (Lisciandro et al. 2009; Lisciandro 2011, 2014, 2016, 2020; Boysen and Lisciandro 2013; McMurray et al. 2016).

The AFAST® examination carries greater potential to positively guide clinical course and improve patient outcome by detecting conditions and complications otherwise missed or delayed based on traditional first line evaluation of physical examination, laboratory testing, and radiographic finding. AFAST® findings are made more clinically relevant for the clinician, client, and referring veterinarian by using its standardized ultrasound format, and by recording AFAST® findings on standardized goal-directed templates for medical records (see below).

The mindset for those using AFAST® is one of a *ruling in* and *ruling out* test (highly specific and highly sensitive) for the presence or absence of free fluid, and a *ruling in* test for soft tissue abnormalities of its target-organ (highly specific and variably sensitive). In other words, AFAST® serves as a screening test for obvious abnormalities of its target-organs, meaning if you see the abnormality it's likely real, however, if you don't see an abnormality, then it may have been missed, being user dependent. Importantly, the AFAST® does not replace a complete detailed abdominal ultrasound.

Moreover, AFAST® serves as a means to better survey veterinary patients and to better keep alive for gold standard testing and treatment. Along with its AFAST®-applied abdominal fluid scoring system, AFAST® helps decision-making regarding medical versus surgical cases including the need for blood transfusion(s), exploratory surgery, and other interventions in bleeding and non-hemorrhaging patients. Finally, the Global FAST® Approach, better ensures that more traditional complete ultrasound studies are ordered for the *correct* cavity and that it is safe to restrain the patient especially for dorsal recumbency.

The standardization and clarity of Global FAST®, the term used for combining AFAST®, TFAST® and Vet BLUE®, is the author's recommended approach for using FAST and point-of-care ultrasound (POCUS) because it avoids "selective imaging" and "satisfaction of search error." "Selective imaging" leads to confirmation bias, searching for evidence to fulfill the clinician's preconceived bias for the diagnosis.

“Satisfaction of search error” is common in radiology and occurs when the evaluator stops at the first abnormality carrying the potential to miss other important findings. Advantageously, the Global FAST® Approach provides exact clarity to an unbiased set of 15 data imaging points of the abdomen and thorax, including heart and lung (Lisciandro 2011, 2012, 2014, 2020); and should preempt all other point-of-care ultrasound examinations. *The bottom line, POCUS examinations should be considered as an add-on to Global FAST®, or the 2 approaches should be used together to avoid such errors.*

The Global FAST® Approach is a 3rd standardized veterinary ultrasound examination for patient imaging and should be a first line extension of the physical exam in most if not all patients (Lisciandro 2020).

Distinguishing Global FAST® from Flashing and POCUS

Global FAST®. Global FAST® is the combination of AFAST® and its Target-organ Approach and its Abdominal Fluid/Hemorrhage Scoring System, TFAST® for the detection of pleural and pericardial effusion, pneumothorax, and its 4 TFAST® echo views, and Vet BLUE®, the veterinary brief lung ultrasound exam, a regional, pattern-based approach with its B-line Scoring System, and its Visual Lung Language. Each of these 3 ultrasound formats has exact clarity to its respective acoustic windows (views) and findings (patient data) are recorded in goal-directed templates. Without this disciplined approach, accurate tracking patients and measuring overall program quality is impossible. Moreover, the veterinary radiologist and cardiologist perform their studies in the exact same manner every time for good reasons, to better know where to expect anatomy, and better recognize deviations from what is expected, and to not miss abnormalities.

Flash exams. The "Flash Approach" is a term applied to a desultory sweep (no organized direction, no defined acoustic windows, no clarity) of the abdomen, thorax, and now lung answering a simple binary question of fluid positive or fluid negative within the abdomen and thorax; and the presence or absence of B-lines (also called lung rockets). The "Flash mentality" should be likened to performing an incomplete physical examination and for most veterinarians we know the risk of missing important clinical information by doing so.

Point-of-care Ultrasound (POCUS). Point-of-care ultrasound (POCUS), which includes FAST (focused assessment with sonography for trauma, triage and tracking) examinations, is defined by the author as a goal-directed ultrasound examination(s) performed by a healthcare provider point-of-care (cageside) to answer a specific diagnostic question(s) or guide performance of an invasive procedure(s).

The Global FAST® Approach is not a "Flash exam." AFAST®, TFAST®, Vet BLUE®, and Global FAST® should never be used interchangeably with the "Flash approach." These terms are erroneously and misleadingly used by our colleagues.

The Global FAST® Approach should be used as a baseline set of unbiased data imaging points surveying both cavities and then POCUS or Focused Exams as add-on evaluations to prevent “selective imaging”, “satisfaction of search error”, and for increasing the probability of an accurate assessment through integration of clinical findings.

Patient Positioning, Preparation, Probe Type, Preset, Probe Maneuver

Positioning. Standing (sternal) and lateral recumbency are used. Right lateral recumbency is preferred over left lateral because of it is advantageous for echocardiography, electrocardiography, and imaging the caudal vena cava, however, the fluid scoring system is validated in either lateral positioning. Generally, if a patient is standing, AFAST® and Global FAST® is performed in standing. In AFAST®-negative standing (sternal) patients,

lateral recumbency is unnecessary. If AFAST®-positive, then follow the “AFAST® 3-minute fluid scoring rule” of moving to lateral recumbency and waiting 3-minutes to allow free fluid to redistribute for an accurate abdominal fluid score. Right lateral recumbency is generally only added to a standing AFAST®- Global FAST® when TFAST® echo views and characterization of the caudal vena cava and its associated hepatic veins are unsatisfactory, or changes in positioning are warranted to better interrogate target-organs. *Dorsal recumbency is never used because it is too risky for hemodynamically fragile or unstable patients especially with intrathoracic problems including cardiac and pulmonary conditions and pleural space disease.*

Preparation. Fur is not shaved but rather parted with minimal amounts of isopropyl alcohol followed by alcohol-based hand sanitizer because it couples as well as commercially available gel with the advantage of evaporating off the patient. Alcohol-based hand sanitizer is also less noxious and less cooling than isopropyl alcohol; and less gooey (hand sanitizer evaporates) than acoustic coupling gel. Isopropyl alcohol should not be used if electrical defibrillation is anticipated (fire/burn hazard).

Make every attempt to part the fur and place the probe as directly as possible on skin to maximize the image quality and minimize “air-trapping” between the probe head and the skin.

Probe Type. The microconvex curvilinear probe is used for the entire Global FAST®. A phased-array (sector) cardiac probe and linear probe may be used but each are unnecessary for most patients only adding more time and are generally reserved for more complete detailed examinations.

Preset. The entire AFAST® and Global FAST® are performed with the abdominal preset. Preset may be changed, but by doing so generally only adds time and changing presets may be reserved for more complete detailed examinations.

Probe Maneuver. The probe maneuvering is standardized. The probe is fanned, rocked cranially and returned to the starting point at each AFAST® view. We base this probe maneuvering on the Boysen et al. study that showed when comparing longitudinal to transverse views, they matched 397/400 times for the detection of free fluid. *All AFAST® views are imaged by fanning, rocking cranially and returning to the starting point.*

The AFAST®

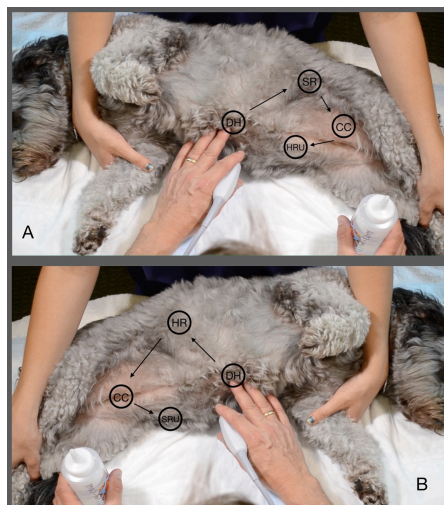


Figure. The AFAST® views used for abdominal fluid scoring are shown on a dog and analogous for cats (and non-human primates and exotic companion mammals). Note not shown is the Hepato-Renal 5th Bonus view when in right lateral and the Spleno-Renal 5th Bonus view when in left lateral recumbency. *This material is reproduced with permission of John Wiley & Sons, Inc., Point-of-Care Ultrasound Techniques for the Small Animal Practitioner, 2nd Edition, Wiley ©2020 and Greg Lisciandro, Hill Country Veterinary Specialists, FASTVet.com © 2014, 2020.*

AFAST® Order. The AFAST® regardless of positioning (standing/sternal, right lateral recumbency) is always performed in the same order beginning at the Diaphragmatico-Hepatic (DH) view, followed by the least gravity dependent Spleno-Renal (SR) view, then the Cysto-Colic (CC) view, completing the AFAST at the most gravity dependent Hepato-Renal Umbilical (HRU) view, where abdominocentesis is performed in most fluid-positive patients. The spleen is generally identified in this region (HRU) and then followed performing a Focused Spleen. In left lateral recumbency the order is analogous with the Hepato-Renal (HR) view replacing the Spleno-Renal view and the Spleno-Renal Umbilical (SRU) view replacing the Hepato-Renal Umbilical view. As with right lateral recumbency, a Focused Spleen is performed *after* completing these 4 views of the AFAST fluid scoring system.

Diaphragmatico-Hepatic (DH) view. Target-organs are liver, gallbladder and the heart, lung, and pleural cavity looking beyond (cranial to) the diaphragm and the caudal vena cava and its associated hepatic veins as it traverses the diaphragm. They are imaged in longitudinal planes with fanning, rocking cranially, and returning to your starting point.

Soft Tissue Abnormalities Screened for at the DH View:

- Gallbladder sludge
- Choleliths
- Gallbladder wall edema
- Gallbladder wall masses
- Mucocoeles
- Liver masses
- Caudal vena cava characterization (and hepatic veins)
- Pericardial effusion
- Pleural effusion
- Lung lesions long the pulmonary-diaphragmatic interface

Spleno-Renal (SR) view. Least gravity-dependent view. Target-organs are left kidney and spleen where it is attached to the greater curvature of the stomach via the short gastric vessels. They are imaged in longitudinal planes with fanning, rocking cranially, and returning to your starting point. The stomach and colon are deep to the target-organs and often air-filled shadowing through the far field. This view would be used for the detection of pneumoperitoneum (air would rise).

Soft Tissue Abnormalities Screened for at the SR (and HR) View:

- Retroperitoneal effusion
- Pyelectasia
- Hydronephrosis
- Perirenal fluid
- Perinephric cysts

- Cortical cysts
- Renal masses
- Splenic masses
- Perirenal and retroperitoneal masses

Cysto-Colic (CC) view. Target-organ is the urinary bladder with the acknowledgement of the colon that when air-filled obscures imaging. Probe (scanning plane) is directed into the most gravity-dependent “CC Pouch.” They are imaged in longitudinal planes with fanning, rocking cranially, and returning to your starting point. The thigh is often seen through the far field. In predominately intact species, such as non-human primates and exotic companion mammals, the sex organs, especially the uterus, should be part of this view.

Soft Tissue Abnormalities Screened for at the CC View:

- Sediment
- Calculi
- Bladder wall masses
- Bladder wall irregularities
- Thrombus

Hepato-Renal Umbilical (HRU) view. Misnomer. The view previously designated Hepato-Renal (HR) view is now considered the “Hepato-Renal Umbilical (HRU) view.” Target-organs are really the spleen and intestine. Neither the right kidney nor the right liver is imaged. The probe is placed at the level of the umbilicus and imaged its scanning plane into the most gravity-dependent “HR Umbilical Pouch.” In standing or sternal, the probe as placed on the umbilicus, Fanning, rocking cranially, and returning to the starting point is the same probe maneuver at all AFAST® views. In predominately intact species, such as non-human primates and exotic companion mammals, the sex organs, especially the uterus, should be part of this view. This view really should be renamed as the “Spleno-Intestino Umbilical view.”

Soft Tissue Abnormalities Screened for at the HR5th Bonus (SR5th Bonus) View:

- Abnormalities of the splenic parenchyma
- Splenomegaly
- Myelolipomas
- Splenic masses
- Mid abdominal masses
- Abnormalities of the splenic hilar vessels
- Small intestinal peristalsis

GOAL-DIRECTED TEMPLATE FOR AFAST®

Patient positioning: right or left lateral recumbency or standing or sternal

Gallbladder: present or absent, contour, wall, content, unremarkable or abnormal

Urinary bladder: present or absent, contour, wall, content, unremarkable or abnormal

Positive of negative at the 4-views (0 negative, 1 positive)

Diaphragmatico-Hepatic (DH) site:	0 or 1/2 or 1
Spleno-Renal (SR) site:	0 or 1/2 or 1
Cysto-Colic (CC) site:	0 or 1/2 or 1

Hepato-Renal Umbilical (HRU) site: 0 or 1/2 or 1

Total Abdominal Fluid Score (0-4): _____

HR5th Bonus View: 0 or 1/2 or 1 or Indeterminate or Not Assessed (NA)

Focused Spleen (*add-on after completing the AFAST® HR Umbilical View*): _____

DH View:

Pleural effusion: absent, present (mild, moderate, severe) or indeterminate or NA

Pericardial effusion: absent, present (mild, moderate, severe) or indeterminate or NA

§Hepatic venous distension: unremarkable or present (Tree Trunk Sign) or indeterminate or NA

&Caudal vena cava characterization: bounce (unremarkable) or FAT or flat or indeterminate or NA

#Vet BLUE: B-lines: 0, 1, 2, 3, >3, or ∞ and if Shred__cm, Tissue__cm, Nodule__cm, Wedge__cm

Comments: _____

Note: The AFAST® is a rapid ultrasound examination used to detect the presence of free abdominal fluid and obvious soft tissue abnormalities as a screening test in order to better direct resuscitation efforts and diagnostics, detect complications, and manage patients. AFAST® is not intended to replace a complete detailed abdominal ultrasound exam.

§The hepatic veins should *not* be apparent in both dogs and cats placed in lateral recumbency. When imaged the branching has been referred to by the author as the "Tree Trunk Sign."

&The caudal vena cava can be alternatively referred to as a bounce = fluid responsive cava (~35-50% diameter change); FAT = fluid intolerant cava (distended with maximum height > 1 cm in dogs < 9kg and > 1.5 cm in dogs > 9kg with little height change [< 10%]); flat = hypovolemic cava (small with maximum height < 3 mm in dogs < 9 kg, < 5 mm in dogs > 9 kg with little height change [< 10%]).

#Vet BLUE screens for lung abnormalities along the Pulmonary-Diaphragmatic Interface.

Template provided by Dr. Gregory Lisciandro, DVM, DABVP, DACVECC, FASTVet.com and Hill Country Veterinary Specialists Copyright 2018, 2019, 2020 for your use and modification.

Other current Goal-directed Template AFAST®, TFAST®, Vet BLUE® and Global FAST® versions may be found at FASTVet.com under the Premium Membership, then Resource Library, and then Free Resources.

References & Further Reading

1. **Lisciandro GR**, Lagutchik MS, Mann KA, et al. Evaluation of an abdominal fluid scoring system determined using abdominal focused assessment with sonography for trauma (AFAST) in 101 dogs with motor vehicle trauma. *J Vet Emerg Crit Care* 2009; 19(5):426-437.
2. Boysen SR, Rozanski EA, Tidwell AS, et al. Evaluation of a focused assessment with sonography for trauma protocol to detect free abdominal fluid in dogs involved in motor vehicle accidents. *J Am Vet Med Assoc* 2004; 225(8):1198-1204.
3. **Lisciandro GR**. Focused abdominal (AFAST) and thoracic (TFAST) focused assessment with sonography for trauma, triage and monitoring in small animals. *J Vet Emerg Crit Care* 2011;20(2):104-122 .
4. **Lisciandro GR**. Chapters 2: The Abdominal (AFAST) Exam; Chapter 16: Focused or COAST³ - CPR, Global FAST and FAST ABCDE. In Focused Ultrasound for the Small Animal Practitioner, Editor, Lisciandro GR. Wiley Blackwell: Ames IA 2014.

5. **Lisciandro GR.** Chapter 55: Ultrasound in Animals. *In Critical Care Ultrasound (human textbook)*, Editors Lumb and Karakitsos. Elsevier: St. Louis, MO 2014.
6. **Lisciandro GR.** Evaluation of initial and serial combination focused assessment with sonography for trauma (CFAST) examination of the thorax (TFAST) and abdomen (AFAST) with the application of an abdominal fluid scoring system in 49 traumatized cats. *J Vet Emerg Crit Care* 2012;22(2):S11.
7. **Lisciandro GR.** Lisciandro GR. The use of the diaphragmatico-hepatic (DH) view of the abdominal and thoracic focused ultrasound techniques with sonography for triage (AFAST/TFAST) examinations for the detection of pericardial effusion in 24 dogs (2011-2012). *J Vet Emerg Crit Care* 2016;26(1):125-31.
8. **Lisciandro, GR.** Alanine aminotransferase level (ALT) as a marker for hemoabdomen detected by abdominal FAST (AFAST) in dogs with automobile trauma. *Abstract, J Vet Emerg Crit Care*, 2014; 24(S1):S11.
9. McMurray J, Boysen S, Chalhoub S. Focused Assessment with Sonography in Non-trauma dogs and cats in the emergency and critical care setting. *Abstract. J Vet Emerg Crit Care*, 2014; 24(S1):S28.
10. **Lisciandro GR.** Abdominal FAST (AFAST)-detected Hemorrhagic Abdominal Effusion in 11 Dogs with Acute Collapse and Gallbladder Wall Edema (Halo Sign) with Presumed Anaphylaxis. *Abstract, J Vet Emerg Crit Care* 2016.
11. **Lisciandro GR.** Alanine aminotransferase level (ALT) as a marker for hemoabdomen detected by abdominal FAST (AFAST) in dogs with automobile trauma. *Abstract, J Vet Emerg Crit Care*, 2014.
12. Hnatusko AI, Gicking JC, **Lisciandro GR.** Anaphylaxis-related hemoperitoneum in 11 dogs. *J Vet Emerg Crit Care, In Press* 2019.
13. **Lisciandro GR,** Fosgate GT, Romero LA, et al. The Expected Frequency and Amount of Free Peritoneal Fluid Estimated Using the Abdominal FAST-applied Abdominal Fluid Scores in Clinically Normal Adult and Juvenile Dogs. *J Vet Emerg Crit Care, In Press* 2019.
14. Higgs VA, Rudloff E, Kirby R, et al. Autologous blood transfusion in dogs with thoracic or abdominal hemorrhage: 25 cases. *J Vet Emerg Crit Care* 2015; 25(6): 731-738.
15. Cole LP, Humm K. Twelve autologous blood transfusions in eight cats with hemoperitoneum. *J Feline Med Surg* 2018; Jul 1:1098612X18785742. doi: 10.1177/1098612X18785742. [Epub ahead of print].
16. Robinson DA, Kiefer K, Bassett R, et al. Autotransfusion in dogs using a 2-syringe technique. *J Vet Emerg Crit Care* 2016; 26(6): 766-774.
17. Narasimhan M, Koenig SJ, Mayo PH. A Whole-Body Approach to Point of Care Ultrasound. *Chest* 2016; 150(4): 772-776.
18. Culp WT, Weisse C, Kellog ME, et al. Spontaneous hemoperitoneum in cats: 65 cases (1994-2006). *J Am Vet Med Assoc* 2010; 236(9): 978-982.
19. **Lisciandro GR.** Chapter 3: Point-of-care Ultrasound. *In: Small Animal Diagnostic Ultrasound*, 4th Edition, edited by Mattoon JS, Sellon RK, and Berry CR. Elsevier: St. Louis, MO, *In Press* 2019.